

MINERVA

CARDIOANGIOLOGICA

VOLUME 65 · No. 1 · FEBRUARY 2017



EDIZIONI · MINERVA · MEDICA

REVIEW

## Peripheral use of detachable coils: expanding the boundaries of embolization

Gianluigi ORGERA<sup>1</sup>, Marcello A. TIPALDI<sup>1</sup>, Iftikhar ZAMAN<sup>2</sup>, Tariq ALI<sup>2</sup>,  
Alberto REBONATO<sup>3</sup>, Adam HATZIDAKIS<sup>4</sup>, Michele ROSSI<sup>1</sup>, Miltiadis E. KROKIDIS<sup>2\*</sup>

<sup>1</sup>Department of Radiology, Sant'Andrea Hospital, Faculty of Medicine and Psychology, Sapienza University, Rome, Italy; <sup>2</sup>Department of Radiology, Cambridge University Hospitals, NHS Foundation Trust, Cambridge, England, UK; <sup>3</sup>Department of Surgical and Biomedical Sciences, University of Perugia, Perugia, Italy; <sup>4</sup>Department of Radiology, University Hospital Heraklion, Medical School of Crete, Heraklion, Greece

\*Corresponding author: Miltiadis E. Krokidis, Department of Radiology, Cambridge University Hospitals NHS Trust, Hills Road, CB2 0QQ, Cambridge, England, UK. E-mail: [mkrokidis@hotmail.com](mailto:mkrokidis@hotmail.com)

### ABSTRACT

Percutaneous embolization was introduced in the mid-'70s and is now an established therapeutic procedure in current medical practice. With the use of improved imaging techniques, smaller profile catheters and new tools, embolization boundaries are significantly expanded in the last decades. Detachable coils were initially introduced in neuroradiology and are now part of the everyday peripheral embolization armamentarium. Purpose of this review article is to present an overview of the expanded possibilities that this novel material is offering in the field of peripheral embolization procedures.

(Cite this article as: Orgera G, Tipaldi MA, Zaman I, Ali T, Rebonato A, Hatzidakis A, *et al.* Peripheral use of detachable coils: expanding the boundaries of embolization. *Minerva Cardioangiologica* 2016;65:52-60)

**Key words:** Therapeutic embolization - Angiography - Endovascular procedures.

Coils are permanent embolization agents that cause mechanical vessel occlusion through thrombus formation. The inception of coil technology in 1970s as an embolization agent has revolutionized the non-surgical management of bleeding and the expansion to other vascular pathologies arrived very quickly.

The first coil that was developed was a 5-cm-long curled segment of a 0.038-inch guide wire with strips of wool attached to its surface.<sup>1</sup> Scientific advancement over the course of time led to the creation of different types of coils, which are now available in everyday clinical practice. The vast majority is made from platinum due to its properties (*i.e.*

malleability and easy visualization under fluoroscopy) and have fibers attached made from a variety of materials (*i.e.*, nylon, Dacron, wool).<sup>2</sup> The intravascular deployment of coils causes intimal damage, resulting in release of thrombogenic factors, thereby promoting thrombosis.<sup>3</sup>

Coils are available in various shapes (*i.e.* helical, straight, tornado, 3D, diamond), sizes (0.035" or macro coils and 0.018"-0.010" or micro-coils) and lengths (1 mm to 60 cm). The size and length of the selected coil to be used depends on the vessel that is embolized. Furthermore, coils can be classified on the basis of their delivery system as pushable or detachable.

### Pushable coils

Pushable coils are loaded into the carrying catheter and then literally pushed-out of the catheter. When the coil reaches the distal end of the catheter cannot be pulled back and has to be deployed. The endovascular community to treat a variety of vascular pathologies has used pushable coils for decades. However in case of coil deployment in an erroneous site the coil needs to be snared and this is not always possible. Therefore, the use of pushable coils may lead in some challenging cases to non-target vascular blockage.<sup>4</sup> To overcome this issue, detachable coils were developed.

### Detachable coils

Detachable coils may be pulled back even though when most of the coil is out of the carrying catheter. Detachable coils involve the proximal end of coil attached to an end of the pusher wire and the coil is released by a detachment mechanism that may be mechanical or electrical.<sup>3</sup>

Mechanical detachment is usually based on an interlocking or a screw release mechanism. The interlocking mechanism involves a small arm on the distal end of pusher wire latched on to the interlock arm located on the proximal end of the coil. Following interlocking, the two ends remain connected whilst still inside the lumen of the carrying catheter. It is following the passage outside the catheter tip that the two interlocking arms separate causing the coil to be detached from the pusher wire and be deployed. While still interlocked, the coil position can be readjusted prior to final deployment.<sup>3, 5</sup> The screw-release mechanism involves the proximal coil end and the end of the wire attached via their respective spiral threads. A mandrill is passed through the wire and the coil. The coil is fastened onto the wire in a clockwise rotation and therefore to detach the coil, the wire needs to be manipulated counter clockwise.<sup>3, 6</sup>

Electrical detachment relies on the introduc-

tion of electrical current to result in detachment of the coil from the delivery wire it is affixed to. These coils were initially used in neuroradiology but are now also used in peripheral interventions.

There are several advantages that detachable coils offer. Firstly, repositioning of the coil within the vasculature before the final deployment is possible. This allows a more precise and controlled deployment of coils during embolization, reducing the risk of coil migration and non-targeted embolization with its associated complications. Furthermore, longer and fewer coils may be employed and reduce the overall procedure cost.

The advantages of detachable coils over the pushable ones in clinical use according to the literature evidence are exposed in the following paragraphs.

### Results of clinical studies with detachable coils

#### *Internal iliac artery embolization prior to EVAR*

Kim *et al.*<sup>7</sup> carried out a retrospective review on 40 patients with aortic aneurysms to assess the effectiveness of detachable interlock microcoils for the embolization of the internal iliac artery previous to endovascular abdominal aneurysm repair for the prevention of type II endoleaks. In 16 patients embolization of the internal iliac artery was required. In 13/16 patients detachable interlock microcoils were used whereas in the remaining 3 a plug was used instead. All the coil cases were technically successful, with no occurrence of procedure-related complications. In all cases, type II endoleak was not observed with computed tomographic angiography during the median follow-up of 3 months (range 1-27 months) and the median clinical follow-up of 12 months (range 1-27 months). Only 2 out of 13 patients were found to have had clinical side effects (such as buttock pain), but the side effects resolved upon follow up, and no long-term complications were reported.

### *Gastroduodenal artery embolization*

Dudeck *et al.*<sup>8</sup> performed a prospective randomized study on 50 patients with the use of standard pushable coils vs interlock detachable coils for the embolization of the gastroduodenal artery (GDA) prior to selective internal radiotherapy (SIRT). The parameters that were evaluated were procedure time, radiation dose, number of devices, complications, and durability of vessel occlusion at follow-up angiography. Firstly, contrary to the pushable coil group, no coil migration occurred with the use of interlock coils. This confirmed the role of interlock detachable coils for precise controlled embolization, with the ability to retrieve or reposition the coil before final delivery. This trial further revealed significantly shorter intervention time with a smaller amount of contrast and thus radiation dose needed with the use of interlock coils as compared to the group where pushable coils were used. A fewer number of coils were needed to obtain embolization using detachable interlock coils as compared the pushable ones.

Park *et al.*<sup>9</sup> in a prospective study of 50 patients compared pushable and detachable coils during embolization of the GDA prior to hepatic artery infusion chemotherapy. The authors' reiterated similar results with the use of detachable coils to be associated with fewer coils, shorter intervention duration and greater precision during deployment.

### *Pulmonary arteriovenous malformations*

Soft detachable microcoils have been increasingly applied in the embolization of pulmonary arteriovenous malformations (PAVMs) because they can be repositioned, offer more precise deployment, and prevent systemic coil migration. Osuga *et al.*<sup>10</sup> reported their experience with the use of detachable coils (bare and hydrogel coated) in a retrospective study of 7 patients with 9 simple-type PAVMs with relatively small feeders (median of 4 mm), obtaining a median size reduction rate 95.0% (range 81.8-99.0%) during the median follow-up period of 10 months. These results are

higher than the other reported in literature and suggest that detachable coils and in particular hydrogel coated ones thanks to their proprieties should be considered more often.

### *Renal arteriovenous malformations*

Treatment for renal AVMs has evolved from open nephrectomy to embolization. Extreme precision is required in such cases to avoid coil migration in the venous territory and to avoid any ischemic complications to the renal parenchyma. Mechanically-detachable coils have been used in the past to embolize renal AVFs.<sup>11</sup>

Mori *et al.*<sup>12</sup> in the early days of use of detachable coils reported a case of a 70-year-old female patient with a large idiopathic renal arteriovenous fistula (AVF) that was treated with detachable coils. The authors had to use a "pre-framing technique" technique of anchoring with a micro catheter in order to avoid the risk of migration — even of the detachable device — due to the extremely high flow. The microcatheter was coiled in the fistulous tract with proximal balloon occlusion. The 0.018" microcoil was then loaded in the micro catheter and, by the gradual withdrawal of the catheter, deployed. This technique requires a small side branch in the fistula that can be used to support the tip of the micro wire over which the micro catheter can be coiled. Altit *et al.*<sup>13</sup> treated very large renal AVFs with multilobulated arterial aneurysms using Microplex-18 framing microcoils (Terumo, Somerset, NJ, USA) followed by Azur Hydrocoils (Terumo) in two sessions. Sundarakumar *et al.*<sup>14</sup> described a new method, in a case report of a 45-year-old male patient, for treatment of renal AVF with solely IDC coils.

### *Pelvic and extremity arteriovenous malformations*

The pelvis is a relatively common site for high flow AVMs. The most common pattern is a multivessel supply from the hypogastric artery, inferior mesenteric artery, middle sacral and common femoral branches with drainage

into the hypogastric vein. One of the most complex but of highly effect treatment in this situation is a combined arterial and venous embolization and this approach is most effective when there is an aneurysmally-dilated draining vein that can be accessed. Conway *et al.*<sup>15</sup> reported the results of embolization for high flow arteriovenous malformation with a dominant outflow artery in 14 patients using detachable coils and plugs. They obtained good results suggesting that this treatment should be considered in selective patients.

### Visceral abdominal aneurysms

Visceral abdominal aneurysms (VAA) are rather rare however may be fatal if undiagnosed.<sup>16</sup> The majority of VAA (about 78%) are detected as incidental findings in cross sectional examinations performed for different reasons.

Several endovascular embolization techniques have recently been developed to manage aneurysms with heterogeneous anatomical features.<sup>17</sup> Detachable coils play a crucial role in such challenging procedures. Kasirajan *et al.*<sup>18</sup> in 2001 first described a retrospective study, in which, twelve embolization proce-

dures of VAA with detachable coils were reported. They concluded that percutaneous transcatheter detachable coil deployment is an effective alternative to open surgery for the management of VAAs and may decrease the morbidity and mortality of the open surgical procedure while preserving flow in the native vessel.

The detachable coils made a huge difference when the “packing technique” has been adapted from neurointervention in the treatment of VAAs. This technique consists of filling the sac with coils, obtaining a certain density that affirms the complete exclusion of the lesion from the general circulation. Loffroy *et al.*<sup>19</sup> reported a technical success rate of 100% in 12 thin neck pseudoaneurysms treated with the packing technique using detachable coils of different calibers and lengths. One patient with a secondary bleeding from arterio-digestive fistula underwent successful surgery. No major complications or late recanalization occurred during a mean 24.7 months of follow-up.

In another study Yasumoto *et al.*<sup>20</sup> analyzed 42 patients with VAA treated with packing technique using interlocking detachable coils of four different types, confirming 100% technical success, defined as absence of flow in

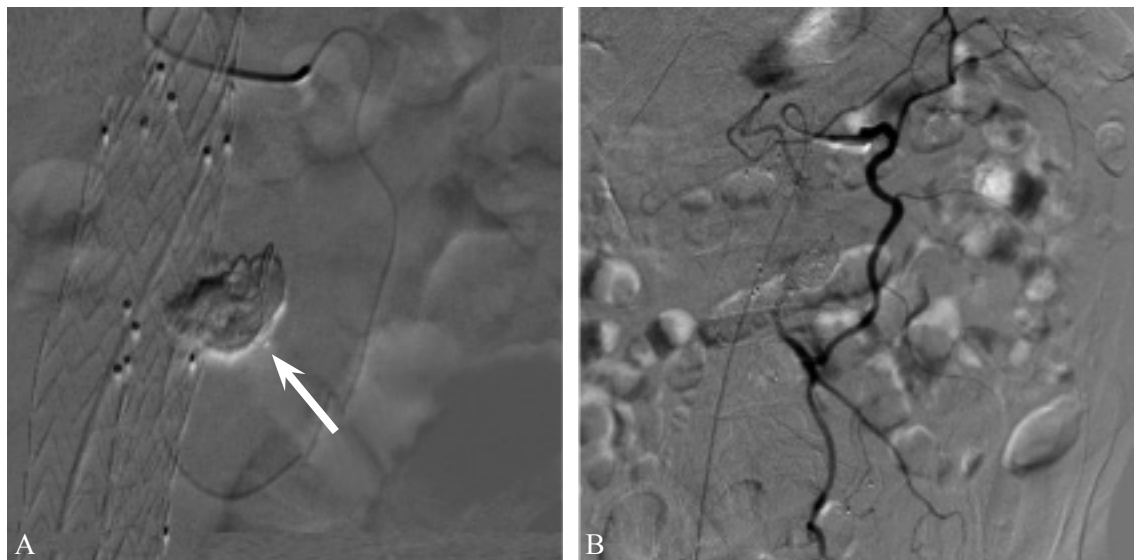


Figure 1.—Embolization of a type II endoleak from the IMA with Onyx (ev3, Covidien Vascular Therapies, Irvine, CA, USA) and a single 5×200-mm detachable coil (Concerto™ Detachable Coil System, ev3, Covidien Vascular Therapies, Irvine, CA, USA). A microcatheter (Progreat, Terumo Corp.) was advanced from the SMA to the IMA through the arc of Riouan.



the aneurysm sac. The follow-up revealed coil compaction in two splenic aneurysms and one hepatic artery aneurysm; recanalization occurred in 12 patients at 24±12 months, two of them with concurrent compaction. The author reported that the incidence of compaction and recanalization do not appear to be correlated with the aneurysm site, but only with density of packing and the aneurysm size.

Treatment of wide neck visceral aneurysms

may be more technically demanding and usually requires the combination of more than one technique (balloon- or stent assisted coil embolization). Rossi *et al.*<sup>21</sup> first reported a 3 years of follow-up case of a 74-year-old patient with a 12-mm-wide neck renal artery aneurysm treated with the Penumbra Coil 400™ Embolization System (Penumbra Inc.). These detachable 0.020-inch coils are larger in diameter than other micro coils and are inherently

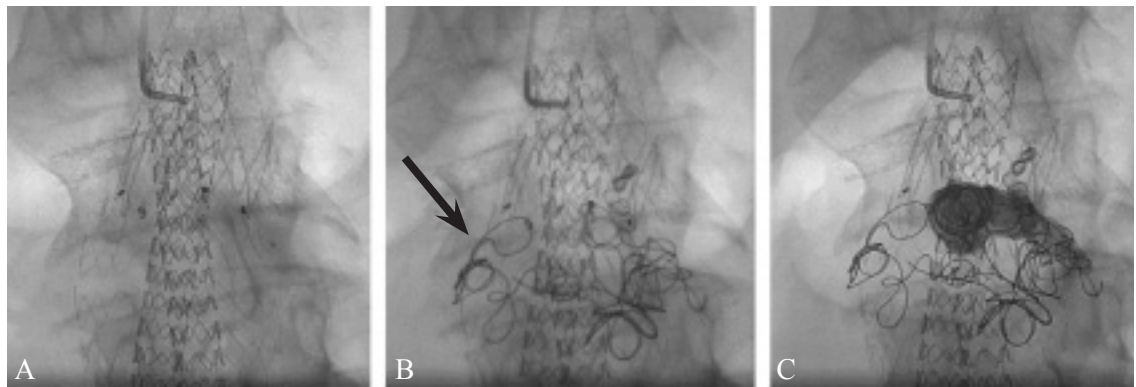


Figure 2.—Embolization of a type Ia endoleak after Nellix (Endologix Inc., Irvine, CA, USA) (positioning with Chimney renal graft in a patient previously treated with an Endurant (Medtronic Inc.). A single 7×300-mm detachable coil (Concerto™ Detachable Coil System, ev3, Covidien Vascular Therapies) was deployed and subsequently Onyx (ev3, Covidien Vascular Therapies) embolization was performed.

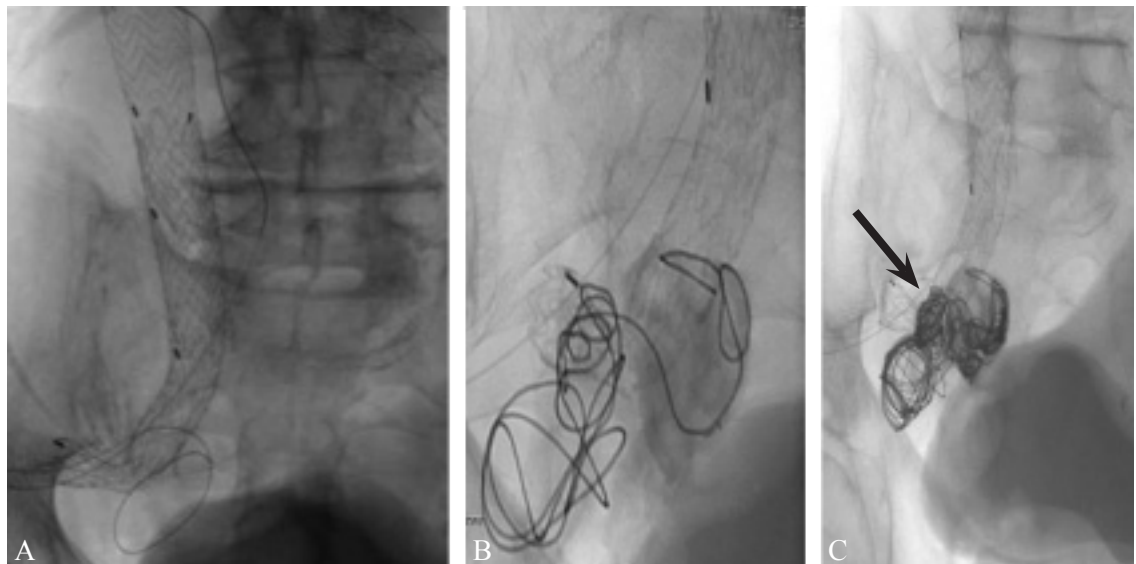


Figure 3.—Percutaneous retrograde embolization from superior gluteal artery for a type II endoleak. A) Under CT guidance the superior gluteal arterial was punctured and a 0.018” inch guide wire was advanced (arrow). Note a second wire (arrow-head) which was deliberately inserted in the superior gluteal vein and was left in situ as reference. B, C) After the catheterization of the aneurysm sac with a 2.7-Fr microcatheter (Progreat, Terumo Corp.), two 7×40-mm and 6×30-mm detachable coils (Ruby, Penumbra) were deployed.

softer due to the fact that come in long diameters (softness increases by the third power of the diameter) and due to the reduced thickness of the nitinol stretch-resistant wire. The coil-within-a-coil design increases the ability of the device to fill the aneurysmal sac with less risk of misplacement. In the mentioned case report each coil was detached only when it was confirmed angiography complete aneurysm exclusion. The first coil, which was used to prevent coil migration through the neck into the parent artery, was the stiffest available and was sized deliberately slightly larger than the aneurysmal dome, thus creating a cage through which the other, more flexible coils could be safely deployed.

Favelier *et al.*<sup>22</sup> reported another interesting case report of a 56-year-old patient with history of kidney transplant and a large, wide-neck pseudoaneurysm at the anastomotic site that appeared three-years post transplantation. Bare stent “caging” technique was used in combination with detachable coils with a very satisfactory result.

### Endoleaks

Standard endovascular treatment options for type Ia endoleaks include the insertion of an aortic cuff to extend graft coverage more proximally, or placement of a large-caliber balloon-expandable stent inside the proximal graft to improve the seal. If an endoleak persists despite these measures or if the placement of an aortic cuff is not technically possible transcatheter embolization needs to be considered instead.

Coil deployment is a good treatment option as reported with good results with both detachable and pushable ones even though the latter are burdened by a significant risk of migration.<sup>23</sup> When dealing with type I endoleaks coils could migrate far in peripheral arteries, causing complication and hampering the retrieval.<sup>24</sup> More over when dealing with large endoleaks, coiling the whole lumen requires a large number of coils; in such cases, the use of long detachable coils allows to reduce the number of devices used, and could be syner-

gic to other embolic agents (*e.g.*, onyx, glue, thrombin). In cases of type II endoleaks many authors reported a direct puncture of the aneurysmal sac or of a gluteal artery under CT guidance with a subsequent successful embolization with detachable coils.<sup>25</sup>

### Discussion

In 1991 Guglielmi invented his eponymous coil and since then the development of new technologies and the best qualities of DSA allowed to improve techniques which became little by little more precise and effective. The evolution from a pushable system to a detachable one emerged a new approach that, especially in the fields of neurointerventional radiology, consented the safe and consistent treatment of vascular disease in a minimally invasive fashion even showing better results than surgery. A review by Andaluz *et al.*<sup>26</sup> of endovascular and microsurgical treatment of aneurysms spanning 1993-2003 using the National Inpatient Sample demonstrated that the frequency of the endovascular procedures doubled, with steady numbers in comparison to surgical aneurysm repair procedures with clipping performed during that time.

The first commercially available detachable coil was relatively stiff for today's standards, and the duration required for detachment ranged up to 45 minutes.<sup>27</sup> The detachment mechanism allowed for controlled deployment, repositioning and removal. Later a three-dimensional coil better known as “framing coil”, was developed and considered as preferable when a pre-determined configuration is required. It acted as a scaffold that covers the wall of an aneurysm allowing a better and safer filling of the sac with the other coils. Another step was the introduction of smaller and softer coils (down to 0.010” inch) based on filamentous core wires and or multiple irregular breakpoints, theoretically allowing a different behavior from small thin helices.<sup>28</sup> Another important development in the architecture and structure of coils was the addition of a polymer filament in the center of the coil that helped to maintain the desired physical characteristic of the implant.

The manufacturing material most commonly used is platinum. Lately, coils with combined materials have also been produced. The rationale of this choice is trying to improve their embolization performance: fibered coil, bioactive coils and hydrogel coils are the principal modified coils actually available. Fibered coils are made with a polymer attached that would allow stopping blood flow by increasing hemostasis and thrombosis. Although their design is of great interest, fibered coils are not widely used and further studies are necessary to assess their use. Bioactive coils are covered externally with substances that stimulate and accelerate the wound healing cascade and cellular ingrowth into the coil conglomerate and into the aneurysm.<sup>29, 30</sup>

Packing density has been associated with a lower rate of recurrence by multiple authors with the most recent data from randomized controlled HELPS trial;<sup>31</sup> this result explains the rationale why softer and modified coils have been developed. In this setting hydrogel coils enable to better fill the sac during aneurysm embolization, thus increasing the packing density of the coil mass.

For most vascular territories, the operator performing an embolization procedure must choose between two different approaches having two very different final outcomes: 1) embolize widely and/or permanently, with potential compromise of end-organ perfusion; or 2) perform a more localized procedure such that the perfusion of distal territories is preserved. The former is generally less challenging and more rapidly applied in emergency situations, but the latter may be preferred to preserve organ function especially in young patients' with bleeding from traumas.

There is a large body of experience and literature concerning the embolic management of individual vascular territories, but, to our knowledge, no comprehensive overview on peripheral use of detachable coils has previously been assembled. This document is an overview that combines the pooled knowledge and standard practice at large-volume institutions with extensive, on-going experience in emergency and elective conditions.

The general review of the literature has shown that the main benefits of these devices are the ability to accurately position reducing the risk of complications, with reduction of coils positioned, minor procedural time and lesser ionizing radiation exposure in front of a higher cost compared to the pushable coil.<sup>7-9, 14, 20, 21</sup> The release of detachable coils may be particularly difficult in tortuous vessels, where this type of coil meets greater resistance to progression compared to normal coil.

Coil embolization technologies success is rapidly changing the landscape of endovascular options for treatment of acute or elective conditions. Continued innovation and refinement of endovascular devices and techniques will ultimately improve technical success rates, reduce procedure-related complications, and broaden the endovascular therapeutic spectrum for varied arterial districts, aneurysms or AVMs morphology. The advance in microcoils and microcatheter technology has enabled selective embolization of small or tortuous vessels, where insertion of the regular delivery catheters is considered difficult or harmful. Especially, soft detachable microcoils, although they are expensive, have been increasingly applied in AVM and visceral pseudoaneurysms embolization, because they can be repositioned, offer more precise deployment, and prevent systemic coil migration.

In the VAA exclusion with packing technique it is crucial to achieve a high packing index value around 24% and the detachable coils can be positioned subsequently to the pushable coils after the aneurysmal sac as been partly filled and when it is higher risk of coil migration. In the VAA exclusion with the sandwich technique the detachable coils can be positioned at the beginning of embolization like an anchor for subsequent pushable coils release, reducing the migration risk.

The cost of detachable coils is higher than of the pushable ones, due to design differences, the largest implantable volume and the presence of additives. However, detachable coils are available in variety of length allowing the use of a fewer number comparing with push-



able, and in determinate setting such as large aneurysm or AVM their use can be limited to the initial phase for safer covering the wall of the lesion, permitting successive filling of the cavity with other embolic agents. Even the use of modified coils, such as the hydrogel polymer coils allow to expand, increasing their diameter resulting in greater filling and vascular occlusion, so that a fewer number of coils are required to achieve embolization with a decrease of the total cost.

We may conclude that, according to our experience and the evidence from the literature detachable coils offer better results than pushable ones and nowadays they need to be part of the everyday interventional radiology armamentarium. The use of pushable coils should be limited to territories of low risk. The evolution however will be in the detachable ones that will become more “intelligent”, in order to satisfy the needs of modern clinical practice.

## References

- Wallace S, Gianturco C, Anderson JH. Therapeutic vas occlusion utilizing steel coil technique: clinical applications. *AJR* 1976;127:381-7.
- Girdhar G, Read M, Sohn J, Shah C, Shrivastava S. In vitro thrombogenicity assessment of polymer filament modified and native platinum embolic coils. *J Neurol Sci* 2014;339:97-101.
- Vaidya S, Tozer K.R, Chen J. An Overview of Embolic Agents. *Semin Intervent Radiol* 2008;25:204-15.
- Travis T, Monsky WL, London J, Danielson M, Brock J, Wegelin J, *et al.* Evaluation of Short-term and Long-term Complications after Emergent Internal Iliac Artery Embolization in Patients with Pelvic Trauma. *J Vasc Interv Radiol* 2008;19:840-7.
- Van Ha TG. Use of the Interlock Fibered IDC Occlusion System in Clinical Practice. *Semin Intervent Radiol* 2008;25:3-10.
- Maleux G, Deroose C, Fieus S, Van Cutsem E, Heye S, Bosmans H, *et al.* Prospective Comparison of Hydrogel-coated Microcoils versus Fibered Platinum Microcoils in the Prophylactic Embolization of the Gastroduodenal Artery before Yttrium-90 Radioembolization. *J Vasc Interv Radiol* 2013;24:797-803.
- Kim WC, Jeon YS, Hong KC, Kim JY, Cho SG, Park JY. Internal Iliac Artery Embolization during an Endovascular Aneurysm Repair with Detachable Interlock Microcoils. *Korean J Radiol* 2014;15:613-21.
- Dudeck O, Bulla K, Wieners G, Ruehl R, Ulrich G, Amthauer H, *et al.* Embolization of the gastroduodenal artery before selective internal radiotherapy: a prospectively randomized trial comparing standard pushable coils with fibered interlock detachable coils. *Cardiovasc Intervent Radiol* 2011;34:74-80.
- Park SI, Lee SJ, Lee M, Lee MS, Kim GM, Kim MD, *et al.* Prospective randomized trial comparing pushable coil and detachable coil during percutaneous implantation of port-catheter system for hepatic artery infusion chemotherapy. *Abdom Imaging* 2015;40:595-600.
- Osuga K, Kishimoto K, Tanaka K, Nakamura M, Ono Y, Maeda N, *et al.* Initial experience with use of hydrogel microcoils in embolization of pulmonary arteriovenous malformations. *Springerplus* 2014;3:609.
- Gomes AS, Mali WP, Oppenheim WL. Embolization therapy in the management of congenital arteriovenous malformations. *Radiology* 1982;144:41-9.
- Mori T, Sugimoto K, Taniguchi T, Tsurusaki M, Izaki K, Konishi J, *et al.* Renal arteriovenous fistula with rapid blood flow successfully treated by transcatheter arterial embolization: Application of interlocking detachable coil as coil anchor. *Cardiovasc Intervent Radiol* 2004;27:374-6.
- Altir R, Brown DB, Gardiner GA. Renal artery aneurysm and arteriovenous fistula associated with fibromuscular dysplasia: Successful treatment with detachable coils. *J Vasc Interv Radiol* 2009;20:1083-6.
- Sundarakum DK, Kroma GM, Smith CM, Lopera JE, Suri R. Embolization of a large high-flow renal arteriovenous fistula using 035" and 018" detachable coils. *Indian J Radiol Imaging* 2013;23:151-4.
- Conway AM, Qato K, Drury J, Rosen RJ. Embolization techniques for high-flow arteriovenous malformations with a dominant outflow vein. *J Vasc Surg Venous Lymphat Disord* 2015;3:178-83.
- Rebonato A, Rossi M, Rebonato S, Cagini L, Scialpi M. Giant hepatic artery aneurysm: a fatal evolution. *J Emerg Med* 2013;45:e217-9.
- Salam TA, Lumsden AB, Martin LG, Smith RB. Non-operative management of visceral aneurysms and pseudoaneurysms. *Am J Surg* 1992;64:215-9.
- Kasirajan K, Greenberg R K, Clair D, Ouriel K. Endovascular Management of Visceral Artery Aneurysm. *J Endovascu Ther* 2001;8:150-5.
- Loffroy R, Rao P, Ota S, De Lin M, Kwak BK, Krause D, *et al.* Packing Technique for Endovascular Coil Embolisation of Peripheral Arterial Pseudo-aneurysm with Preservation of the Parent Artery: Safety, Efficacy and Outcomes. *Eur J Vasc Endovasc Surg* 2010;40:209-15.
- Yasumoto, K. Osuga, Yamamoto H, Ono Y, Masada M, Mikami K, *et al.* Long-Term Outcomes of Coil Packing for Visceral Aneurysm: Correlation between Packing Density and Incidence of Coil Compaction or Recanalization. *J Vasc Interv Radiol* 2013;24:1798-807.
- Rossi M, Varano GM, Orgera G, Rebonato A, Laurino F, De Nunzio C. Wide-neck renal artery aneurysm: parenchymal sparing endovascular treatment with a new device. *BMC Urol* 2014;14:42.
- Favelier S, Kretz B, Tanter Y, Loffroy R. Stent-assisted detachable coil embolization of a late-onset wide-necked anastomotic renal allograft artery pseudoaneurysm. *J Vasc Surg* 2012;56:1131.
- Sheehan MK, Barbato J, Compton CN, Zajko A, Rhee R, Makaroun MS. Effectiveness of coiling in the treatment of endoleaks after endovascular repair. *J Vasc Surg* 2004;40:430-4.
- Lee K, Park HS, Lee T. Rescue therapy of inadvertent coil migration for endovascular treatment of type II endoleak. *Vasc Specialist Int* 2016;32:22-5.
- Parlani G, Simonte G, Fiorucci B, De Rango P, Isernia G, Fischer MJ, *et al.* Bilateral staged CT guided gluteal artery puncture for internal iliac embolization in a patient with type II endoleak. *Ann Vasc Surg* 2016 Jul 13. [Epub ahead of print]
- Andaluz N, Zuccarello M. Recent trends in the treatment of cerebral aneurysms: analysis of a nationwide inpatient database. *J Neurosurg* 2008;108:1163-9.

27. Guglielmi G, Vinuela F, Sepetka I, Macellari V. Electrothrombosis of saccular aneurysms via endovascular approach. *J Neurosurg* 1991;75:1-7.
28. Hui FK1, Fiorella D, Masaryk TJ, Rasmussen PA, Dion JE. A history of detachable coils: 1987-2012. *J NeuroIntervent Surg* 2014;6:134-8.
29. Murayama Y. Matrix and bioabsorbable polymeric coils accelerate healing of intracranial aneurysms: long-term experimental study. *Stroke* 2003;34:2031-7.
30. Linfante I, Akkawi NM, Perlow A, Andreone V, Wakhloo AK. Polyglycolide/polylactide-coated platinumcoils for patients with ruptured and unruptured cerebral aneurysms: a single-center experience. *Stroke* 2005;36:1948-53.
31. White PM, Lewis SC, Gholkar A, Sellar RJ, Nahser H, Cognard C, *et al.*; HELPS trial collaborators. Hydrogel-coated coils versus bare platinum coils for the endovascular treatment of intracranial aneurysms (HELPS): a randomised controlled trial. *Lancet* 2011;377:1655-62.

---

*Conflicts of interest.*—The authors certify that there is no conflict of interest with any financial organization regarding the material discussed in the manuscript.

Article first published online: September 21, 2016.